International Journal of Medical and Health Sciences

Journal Home Page: http://www.ijmhs.net ISSN:2277-4505

Case Report

Eventration of Right Hemidiaphragm With Gastric Volvulus

N.L.N.Moorthy[1],B.Vanaja[2], D.Mahesh Chander[3],P.Jhansi Rani[4]

[1&3]Professors, [2] II Year Resident, [4]Assistant Professor, Department of Radiology, Gandhi Medical College and Hospital, Secunderabad, Telangana, 500020 INDIA.

ABSTRACT

Eventration of right hemidiaphragm is an extremely rare condition. We report a case of eventration of right hemidiaphragm with gastric volvulus in a child presenting as respiratory illness. There were no symptoms related to gastro intestinal tract. Routine chest radiograph and upper GI barium study revealed the presence of organoaxial gastric volvulus with right hemi diaphragm eventration, which was confirmed at surgery. Anterior gastropexy was done and the child was asymptomatic following surgery.

KEYWORDS: Congenital, eventration, gastric volvulus, organoaxial rotation.

INTRODUCTION

Diaphragmatic eventration is an abnormal elevation of diaphragm which can be congenital or acquired, following paralysis of diaphragm, in association with herpes zoster, diphtheria etc. The diaphragmatic muscle may be thin. The symptoms result from either compression of the ipsilateral lung or displacement of abdominal viscera below the elevated hemidiaphragm[1].

Though difficult, it is important to differentiate between congenital diaphragmatic hernia and congenital eventration because eventration has severe perinatal outcome in the form of severe respiratory distress, cyanosis, and respiratory failure compared to diaphragmatic hernia[2]. Eventration is common on the left side. Surgical correction is required only if the symptoms are severe. We report a case of eventration of hemidiaphragm which has occurred on the right side with associated organoaxial volvulus of stomach.

CASE REPORT

A seven year old boy presented with low grade fever, shortness of breath, productive cough of 3 weeks duration. There was no history of abdominal pain or vomiting. Clinical examination showed reduced chest movements on right side with decreased air entry. There was no mediastinal shift. Routine laboratory investigations were within normal limits. The provisional diagnosis based on the above clinical findings was pneumonic consolidation.ESR was normal. Mantoux test and sputum AFB were negative. Routine chest radiograph in PA and lateral projection revealed elevated right hemidiaphragm with large air fluid level below the lung parenchyma. Heart borders were normal [Figure1,2].

Ultrasound scan of the chest showed the presence of right hemidiaphragm at high position with bowel loops below the diaphragm. There was no pleural effusion. Barium esophagogram revealed organoaxial rotation of stomach with inferiorly pointing gastroesophageal junction. Esophagus was normal[Figure 3]. Based on the findings on plain radiography and barium studies, right sided eventration of hemidiaphragm with associated gastric volvulus was diagnosed.

CT plain and with oral contrast was done which confirmed the presence of partial eventration on right side with gastric volvulus[Figure 4]. On surgery, the stomach was distended, eventration of right hemidiaphragm was segmental and was limited to posterior dome of diaphragm. The diaphragm was plicated with rows of 3-0 prolene sutures. Anterior gastropexy was done fixing the stomach at 3 points to anterior abdominal wall. The child remained symptom free at yearly follow up.

Figure 1: Chest radiograph PA view showing elevation of right hemidiaphragm with large air fluid level below the diaphragm with clear lung parenchyma



Figure 2: Chest radiograph right lateral view showing posterior eventration of right hemidiaphragm with a large air fluid level below



Figure 3: Barium esophagogram in erect position shows organoaxial rotation of stomach with reversal of gastroesophageal junction

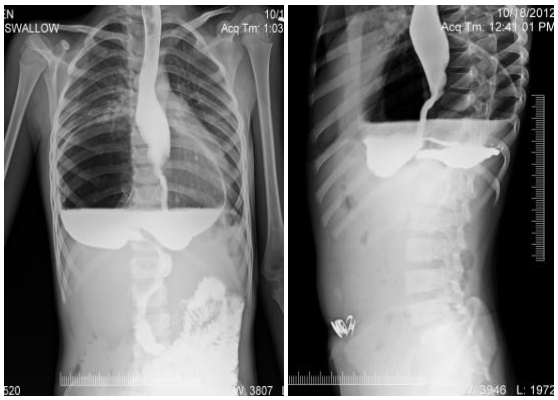

Figure 4: Axial section CT with oral contrast showing the presence of partial eventration on right side with gastric volvulus



DISCUSSION

Eventration is an abnormal elevation of one or part of one, intact leaf of the diaphragm and differs from diaphragmatic hernia in that there is a diaphragmatic defect in the later. It may be congenital or acquired Eventration is more common on the left side and the reported incidence ranges from 1 in 2,800 to 1 in 13,000 live births. These cases usually present with either respiratory or abdominal symptoms due to superior migration of liver and stomach[3]. It may be congenital or acquired. Congenital eventration results from muscular aplasia which occurs in utero. Acquired causes include phrenic nerve palsy which results from adjoining inflammation, trauma or neoplastic pathology.

Congenital type usually presents in childhood where as in adults it is mostly asymptomatic. These cases usually present with either respiratory symptoms like distress or dyspnea on exertion or abdominal symptoms like epigastric pain, belching and dysphagia. Complications of eventration include acute gastric volvulus or chronic recurrent volvulus of splenic flexure of colon. Gastric volvulus is a disease more commonly seen in adults. Abnormal degree of rotation of one part of the stomach around another varying from 180^0 to 360^0 is known as gastric volvulus [4].

Normally the stomach is held securely in place by four ligaments called esophageal hiatus, gastrophrenic ligament, gastrosplenic ligament and duodenum which prevent abnormal rotation.Hence gastric volvulus is rare. It could be primary or secondary. In primary gastric volvulus, there is intact diaphragm with abnormality of suspensory ligaments of stomach. Secondary gastric volvulus is associated with abnormality of diaphragm.

Depending on the axis of rotation of stomach, volvulus can be of three types namely organoaxial, mesenteroaxial and combined types [5,6]. Organoaxial volvulus is less common in children where it may be associated with predisposing factors like eventration , diaphragmatic hernia, hiatus hernia, asplenia, lack of ligaments etc. Because of the rarity of the problem and unusual presenting features, the diagnosis may be difficult.

The clinical symptoms depend on the extent or degree of rotation and gastric outlet obstruction. Children can have acute presentation and classic triad of Borchardt may be seen which includes epigastric distension, violent unproductive retching and inability to pass nasogastric tube.

Symptoms result from dual obstruction of gastroesophageal and pyloric ends. This triad is rarely seen in children where as it may be seen in 30% of adults.

The presentation could be a chronic one, where symptoms are vomiting, abdominal distension and failure to thrive due to intermittent or chronic gastric volvulus [7].There are specific radiological findings in acute and secondary gastric volvulus. In acute organoaxial volvulus, plain film shows distended stomach with an air fluid level and paucity of distal intestinal gas. A notch may be seen on the right border with concavity to right side which is considered to be specific for organoaxial volvulus. Obstruction at the gastroesophageal junction may be seen on barium swallow as 'Bird's beak appearance'. Associated defects like diaphragmatic defects should be looked for as they may be predisposing causes for volvulus [7].

CONCLUSION

Eventration of the diaphragm is sometimes associated with complications like gastric volvulus, The presentation of volvulus may not be specific with gastrointestinal symptoms. Therefore we conclude that gastric volvulus should be kept in mind when any child presents with vague symptoms of respiratory and gastrointestinal system to avoid delay in appropriate therapy and minimize the risk of complications.

REFERENCES

1. Man Mohan Harjai. Rare Congenital Diaphragmatic Defects. In: Prof. Eleanor Molloy, editor. Congenital Diaphragmatic Hernia-Prenatal to Childhood Management and Outcomes, InTech.2012. Available from: http://www.intechopen.com/books/congenital-diaphragmatic-hernia-prenatal-to-childhood-management-and-outcomes/rare-congenital-diaphragmatic-defects.
2. Saleh MK, Suwaid MA, Idris SK, Tabari AM, Isjaku K. Diphragmatic eventration mimicking congenital diaphragmatic hernia:The value of chest radiograph and barium meal in diagnosis. Niger J Basic Clin Sci. 2012;9:36-9.
3. John Caffey. Caffey's Pediatric Diagnostic Imaging.11th Edition.St.Louis: Mosby Elsevier. 2007; Page no 1454-55.
4. Kamlesh K. Tiwari, Chetan Sharma, Vijay Kumar Kundal, Vinita Chathurvedi, RakshaKundal, DeenDayal Sharma, et al. Acute Mesenteroaxial Gastric Volvulus with Eventration of the Diaphragm. Journal of case reports. 2013; 3(2):460-3.
5. Randalphkyle cribs, Kenneth William Glow, Mark Lewis Wulkan. Gastric Volvulus in infants and Children. Pediatrics. 2008;122(3):752-62.
6. Nagdeve N.G, Sarin Y.K.Volvulus Complicating Dextrogastria in an Infant. Indian Pediatr. 2007 Feb; 44(2):142-4.
7. A.K.Singhal, K.G.Vignesh, J. Mathai. Acute gastric volvulus secondary to eventration of the diaphragm in a child. J Indian AssocPediatr Surg. 2006;11:44-6.

*Corresponding author: Dr B.Vanaja
E-Mail: drvanaja.bulkapuram@gmail.com