



Case Report

Huge submandibular Salivary Sialolith - A case Report

Abdalla Saleh Aljabry ^{1*}

¹Dean Faculty of Dentistry, University of Medical Science and Technology and director general of Academic Dental Teaching Hospital, Obaid Khatim, Avenue-Khartoum-Sudan.

ABSTRACT

salivary gland stones constitute a major health problem especially when a major gland is involved. When the stones occupy a large portion of the gland, the whole gland maybe partially or totally excised. Removal of gland results in decreased salivary flow (Xerostomia) which results in gingivitis, difficulty in swallowing and speech. In this case, the stone is formed in the duct so fortunately the gland is saved regardless of the immense size of the stone compared with the relatively young patient.

KEYWORDS: Aljabry, huge sialolith, submandibular.

INTRODUCTION

Salivary glands are located and distributed around the oral cavity. There are three major pairs of salivary glands; parotid, submandibular and sublingual". The most common diseases and disorders that affect these glands are the salivary sialolithiasis[1]. The submandibular salivary glands and their ducts represent the most frequent sites for the salivary gland stones; they represent about 80% of the whole cases of salivary stones while less than 20% occur in the parotid gland[2],[3]Ultrasonography currently represents an excellent first line diagnostic technique; it reveals ductal and highly mineralized stones of at least 1.5mm size with accuracy of 99%.

Conventional sialography in which dye is injected in retrograde way through ductal opening followed by radiography provides high resolution images of salivary ducts but it is contraindicated in acute infections. Small stones present near ductal opening are best visualized by T2 weighted MRI sequences which allow consistent and accurate assessment of salivary glandular calculi. Recent advances in optical technology have led to the development of sialoendoscopy a new diagnostic mean of directly visualizing intra ductal stones which allows complete exploration of duct including shockwaves lithotripsy, sialoendoscopy, interventional radiology, endoscopically video-assisted trans-oral and cervical surgical retrieval of stones, and botulinum toxin therapy.

CASE REPORT

A 27-years old lady presented at the periodontal department in Academy dental teaching hospital (ADTH) complaining of small nodule in the right sublingual region of the floor of the mouth. Extraoral examination revealed that the right submandibular gland is enlarged and tender; the right submandibular lymph nodes are palpable and showed some tenderness. Intraorally, there was small nodule elevating the floor of the mouth at the location of the right submandibular duct (figure 1). The saliva appeared normal in amount and consistency. The mucosa overlying the nodules was normal. Lower occlusal radiograph revealed the presence of long radiopaque rod extending from the right canine to the distal end of the third molar (figure 2). The diagnosis was submandibular salivary gland duct stone.

In the next visit, the stone was removed under local anesthesia; small incision was made over the projection of the stone and the stone was grasped by a hemostat and pulled out in one piece.(figure 3) The stone measured 40mm in total length(figure 4). The patient was given amoxicillin and ibuprofen and dismissed for two weeks. In the next visit, the healing was uneventful as there were no signs of inflammation or swelling and saliva was seen oozing from the reformed duct.

Figure 1: Large nodule elevating the floor of the mouth

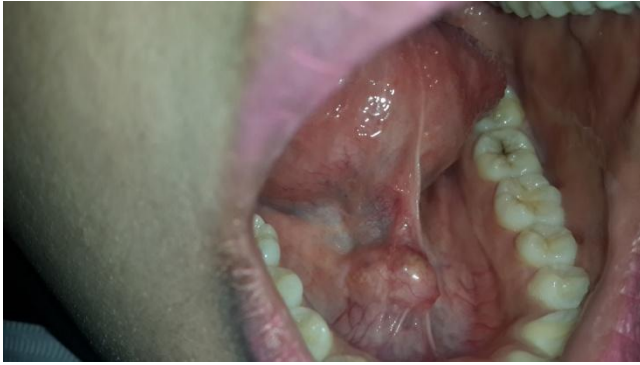

Figure 2: Radiograph shows the entire length of the stone

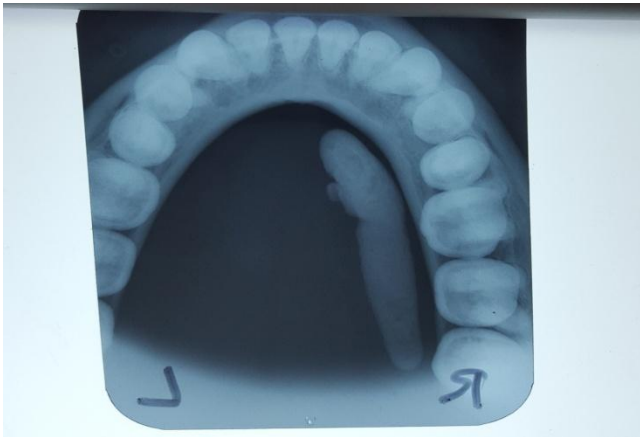


Figure 3: Tip of the stone appearing after the initial incision

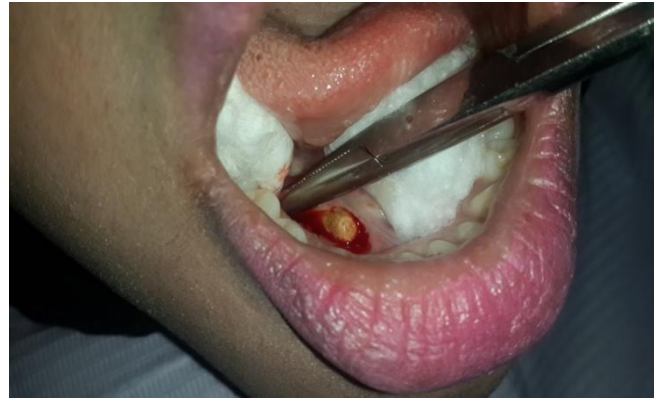

Figure 4: Actual of the stone (4 inches)



DISCUSSION

When large stones are diagnosed, they are usually found in the body of the glands. Large ductal stones were age related but in our case, although the patient is only 27- year old, the stone is very large in all dimensions and occupied the whole length of the duct. Although sialoliths are very frequent, the exact etiology remained unclear. It is suggested that the formation of salivary stones starts by the formation of a central nucleus of inorganic salts, then followed by the deposition of organic and inorganic substances peripherally. This will eventually lead to growth of the calculus[4]. however; recently published data demonstrated cases in which the central part (nidus) is composed of entirely organic material[5].

Takeshita et al reviewed many case reports in Japan in which the central core was of organic nature and concluded that in the majority of cases, a foreign body which is bony, may have penetrated the Wharton's duct through a wound in the floor of the mouth[6]. They also stated that " some sialoliths might result from a retrograde migration of aliments or bacteria within salivary ducts from the oral cavity."

This statement is in accordance with the work of Marchal et Al in which they reviewed the diagnostic sialoendoscopy procedures of 120 cases of submandibular stones and reported that in 90% of cases there is sphincter system in the first 3 cm of the Wharton's duct. Our case is unique in two aspects: the first is the relatively young patient and the second is the immense size of stone. This may potentiate the retrograde migration hypothesis and the presence of sphincter system in the Wharton's duct.

CONCLUSION

The possibility of the retrograde theory is beginning to gain more interest and more evidence but the new diagnostic advancements should be utilized to cast more light on this issue.

Conflicts of interest: There are no conflicts of interest

REFERENCES

1. Trepan M.G,Hohiwal R.L. Multiple salivary calculi in Wharton's duct. The Journal of Laryngology & Otology 1985; 99:1313-1314.
2. Leung A.K, Choi M.C, Wagner G.A. Multiple sialoliths and sialolith of unusual size in the Submandibular duct. Oral Surg, Oral Med, Oral Path, Oral Radiol, Endod 1999; 87: 331-333.
3. Norman J.E.D, McGurk M, eds. Color Atlas and Text of the Salivary Glands diseases, disorders, and surgery . London, England, Mosby-Wolfe; 1995;243-251.
4. Harrison JD, Triantafyllou A, Garrett J R. Ultrastructural localization of microliths in salivary glands of cat. J Oral Pathol Med. 1993;22:358-362.
5. Marchal F, Becker M, Dulguerov P, Lehmann W. Interventional sialoendoscopy. Laryngoscope. 2000; 110:318-320.

6. Cappaccio P, Ottaviani F, Manzo R et al. Extracorporeal lithotripsy for salivary calculi: a long-term clinical experience. Laryngoscope. Jun 2004; 114: 1069-107.

*Corresponding author: Dr Abdalla Saleh Aljabry
E-Mail: abdugab2@yahoo.com