



Case Report

Cyto-Radiological Diagnosis of Macrodystrophia Lipomatosa: A Report of Rare Entity With Review of Literature

Rahul Mannan^{1*}, Tejinder Singh Bhasin², Parampreet Kaur³, Harjot Kaur⁴, Kulwinder Singh⁵

^{1&4}Associate Professors, ²Professor, ³Resident Department of Pathology, SGRDIMSR, Amritsar (Punjab) India.

⁵Associate Professor, Department of Radio-diagnosis, SGRDIMSR, Amritsar (Punjab) India.

ABSTRACT

Macrodystrophia lipomatosa (MDL) is rare congenital hamartomatous lesion causing localized or generalized gigantism of hand or foot. In the paediatric age group; MDL leads to a diagnostic dilemma with fibro-lipohamartoma, neurofibromatosis type 1 (plexiform neurofibroma), lymphangiomatosis, hemangiomas and Klippel-Trenaunay-Weber syndrome, Beckwith Wiedeman syndrome, Mafucci syndrome, Ollier disease and Proteus syndrome.

A 2-year-old female child presented with a progressive disproportionate enlargement of the index and the middle finger of the right hand. Correlating the lesion's clinical presentation and cytological findings a diagnosis of benign mesenchymal lesion of lipomatous origin with differentials of MDL and fibrolipomatous hamartoma (FLH) were suggested. MRI findings also concurred with the cytological diagnosis. Surgical debulking was done and a definitive diagnosis of MDL was given on histopathology.

The present case is worth reporting as it describes a rare case and also highlights the importance of correlating clinical and radiological findings with cytology to reach an early diagnosis.

KEYWORDS: Macrodystrophia lipomatosa, Cytology, Radiology.

INTRODUCTION

Macrodystrophia lipomatosa (MDL) - is a rare congenital disorder. It consists of a hamartomatous lesion which results in gigantism (localized or generalized) of the hand or foot. It occurs mainly in infancy, but can also present in late adulthood [1]. It is characterized by an increase in all the mesenchymal elements, particularly fibroadipose tissue. Earlier, a variety of descriptive terms were used for this condition, especially in the paediatric age group, such as - macrodactyly, megalodactyly, digital gigantism, macromelia, partial acromegaly, macrosomy, and limited gigantism. In the pediatric age group, MDL leads to a diagnostic dilemma and has to be differentiated from various other conditions as they differ in course, prognosis, complications and treatment [2-3]. In the present case report, cytology in conjunction with radio-imaging aided in reaching the diagnosis in a 2 year old child, followed by subsequent corrective surgical management.

CASE REPORT

A 2-year-old female child presented in the pediatric outpatient of a tertiary care centre of north India, with a progressive disproportionate enlargement of the index and the middle finger of the right hand for the last 1 ½ year.

[Figure-1] There was no history of any pain or neurovascular symptoms and also no family history of extremity gigantism. The developmental milestones were according to age. On physical examination, a non tender, soft tissue mass was palpable on the volar aspect of the enlarged fingers. No overlying cutaneous changes, pitting oedema, or bruit were seen. All the other extremities were found to be normal on examination. A plain radiograph demonstrated soft tissue swelling along the volar aspect of the enlarged fingers.

Fine needle aspiration (FNA) of the site was advised. It was done with a 22 G needle by giving 3-4 passes at 2 different sites. Material aspirated was greasy and tinged with blood. Smears were air dried and subsequently stained with May Grunwald Giemsa (MGG) and revealed a fair number of mature adipocytes along with a few spindle cells and stromal fragments. The background contained fat droplets, few RBC's and inflammatory cells. [Figure-2] Correlating the lesion's clinical presentation and cytological findings a diagnosis of benign mesenchymal lesion of lipomatous origin with differentials of MDL and fibrolipomatous hamartoma (FLH) were suggested.

Figure1: Clinical presentation showing enlargement of the index and the middle finger of the right hand.

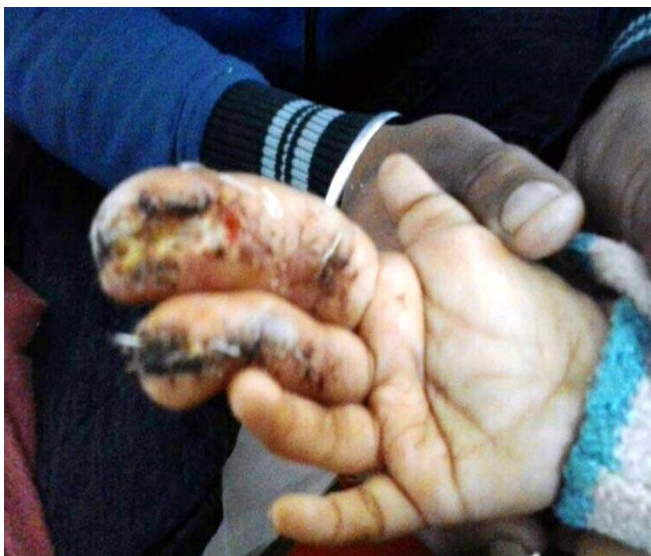
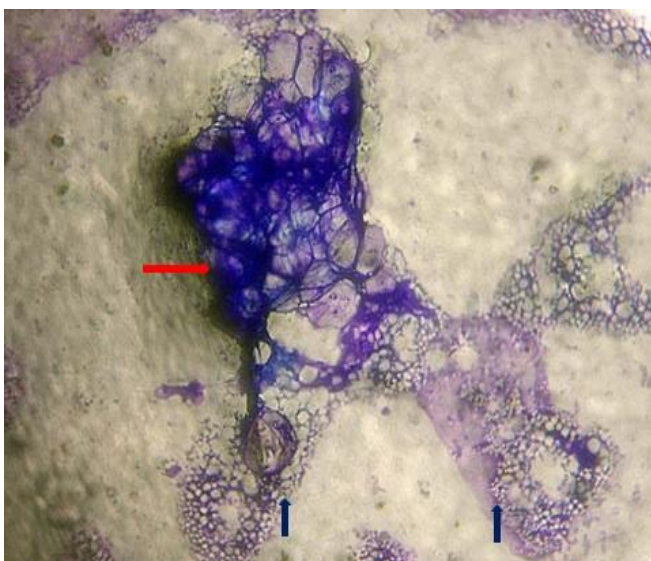


Figure 2: Figure-2: Cytological smears showing fat droplets, mature adipocytes (↑) and stromal fragments composed of spindle cells (↑). (MGG 200 X)

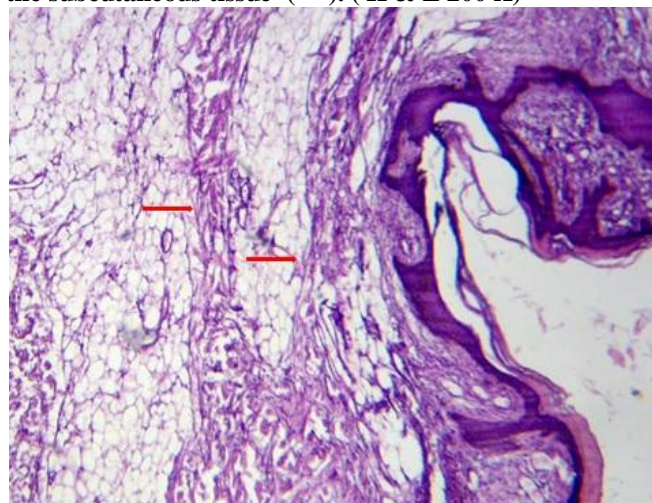


Subsequently, an MRI demonstrated marked proliferation of the subcutaneous fat which was not capsulated. Diffuse bony enlargement as-well-as widening of phalanges of the index and middle fingers, with no significant cortical erosions was also seen. [Figure-3] This was in concurrence with the cytological differential of MDL over FLH. Debulking of the lesion was done and the material sent to the histopathology unit. Multiple pieces were processed and the haematoxylin and eosin (H&E) sections showed increase in adipose tissue scattered in a fine lattice of fibrous tissue involving the subcutaneous tissue [Figure-4], and at places involving the nerve sheath and the muscle fibers. Thus, a definitive diagnosis of MDL was rendered which confirmed the initial diagnosis made on cytology.

Figure 3: MRI demonstrating proliferation of the non-encapsulated subcutaneous fat with diffuse bony enlargement as well as widening of phalanges.

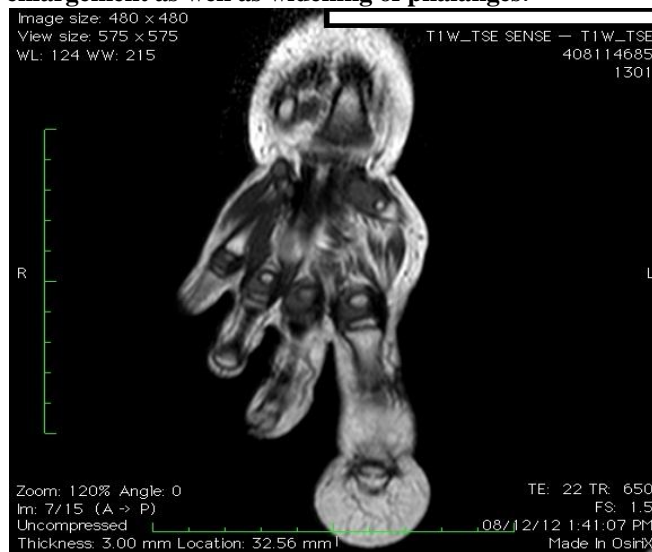

Figure-4: Section demonstrating increase in adipose tissue scattered in a fine lattice of fibrous tissue involving the subcutaneous tissue (↑). (H & E 200 X)



DISCUSSION

The term macrodystrophia lipomatosa (MDL) was first proposed by Feirz. MDL, seen more in males is characterized by an abnormal overgrowth of the mesenchymal elements resulting in gigantism of single or multiple digits or the entire limb- one or both side [4]. MDL may be associated with anomalies like syndactyly, polydactyly, brachydactyly or clinodactyly and also with symphalangism, lipomatous growths in intestines and in other tissues, calvarial abnormalities, pigmented nevus and pulmonary cysts [5-6].

Although the distal upper limb was affected in our case, the lower limb has been reported to be more often involved than the upper limb, and the 2nd and 3rd digits are more frequently affected, which corresponds to the median plantar nerve and median nerve in the lower and upper limbs respectively [7]. Apart from cosmesis; osteoarthritis, deformity and compressive neuropathies are the main complaints of the patient. Various hypotheses regarding the

etiopathogenesis of the entity have been proposed such as lipomatous degeneration, fetal circulation abnormality, damage of extremity bud and errors in the segmentation in intrauterine life and hypertrophy of the concerned nerve [8].

The differential diagnosis of MDL includes fibrolipomatous hamartoma (FLH), neurofibromatosis type 1 (plexiform neurofibroma), lymphangiomatosis, hemangiomas and Klippel-Trenaunay-Weber syndrome, Beckwith Wiedeman syndrome, Mafucci syndrome, Ollier disease and Proteus syndrome. Out of these, a negative family history and absence of neurocutaneous involvement rules out Neurofibromatosis, Mafucci syndrome, Ollier disease and Proteus syndrome [6]. Although hemihypertrophy is noted with Beckwith Wiedeman syndrome, it was ruled out in present case due to a normal ultrasonography (absence of renal mass).

Clinically, Fibrolipomatous hamartoma (FLH) produces digital overgrowth and can be confused with MDL. In contrast to MDL, it usually presents as an isolated nerve lesion and associated with intramuscular fat deposition [9]. MDL is characterized not only by fat deposition in nerve sheaths, subcutaneous and muscle compartment, but also there is involvement of periosteum leading to the bony changes such as hypertrophy, exostosis, ankylosis of interphalangeal joints and fatty invasion of the medullary cavity [10] which can easily be corroborated by radiological findings.

There is osseous hypertrophy and cortical thickening in the affected part of the body and this may lead to exostosis like bony outgrowths from the involved bone. MRI can easily demonstrate the fatty infiltration of the muscles. There may be linear hypointense fibrous bands noted within this abnormal fat. MR imaging also reveals a redundancy of fatty tissue and fibrous thickening of a nerve (demonstration of fat within the nerve) [11].

As the digital enlargement associated with this condition stops at puberty, therefore, along with improving the cosmetic outlook, the stress of the management should include attempt to preserve neurological functions. The management is usually surgical which includes segmental removal in the localized form of the disease to multiple debulking procedures, epiphysiodesis and various osteotomies which are indicated for the more severe form of the disease [6].

CONCLUSION

The present case is worth reporting as it describes a rare case and also highlights the importance of correlating clinical and radiological findings with cytology to reach an early diagnosis.

REFERENCES

1. Kregel S, Fustes-Morales A, Carrasco D, Vazquez M, Duran-McKinster D, Ruiz-Maldonado R: Macroductyly: Report of eight cases and review of literature. *Pediatr Dermat* 2000; 7(4):270-6.
2. Ozturk A, Baktiroglu L, Ozturk E, Yazgan P: Macroductyly lipomatosa: a case report. *Acta Orthop Traumatol Turc* 2004; 38:220-3.
3. Khan RA, Wahab S, Ahmad I, Chana RS. Macroductyly lipomatosa: four case reports- *Italian Journal of Pediatrics* 2010; 36:69.
4. Feriz H. Makroductyly lipomatosa progressiva. *Virchows Arch* 1925; 260:308-68.
5. Goldman AB, Kaye JJ. Macroductyly lipomatosa: Radiographic diagnosis. *AJR Am J Roentgenol* 1977; 128:101-5.
6. Watt AJ, Chung KC. Macroductyly lipomatosa: a reconstructive approach to gigantism of the foot. *J Foot Ankle Surg* 2004; 43(1):51-5.
7. Jain R, Sawhney S, Berry M: CT diagnosis of macroductyly lipomatosa. A case report. *Acta Radiol* 1992; 33:554-5.
8. Ly JQ, Beall DP: Quiz case. Macroductyly lipomatosa. *European Journal of Radiology* 2003; 47(1):16-8.
9. De Maeseneer M, Jaovisidha S, Lenchik L, Witte D, Schweitzer ME, Sartoris DJ, Resnick D. Fibrolipomatous hamartoma: MR imaging findings. *Skeletal Radiology* 1997; 26(3):155-160.
10. Boren WL, Henry REC, Wintch K: MR diagnosis of fibrolipomatous hamartoma of nerve: association with nerve territory- oriented macroductyly (macroductyly lipomatosa). *Skeletal Radiol* 1995; 24:296-7.
11. Blacksin M, Barnes FJ, Lyons MM: MR diagnosis of macroductyly lipomatosa. *American Journal of Roentgenology* 1992; 158(6):1295-7.

*Corresponding author: Dr. Rahul Mannan
E-Mail: rahulmannan@gmail.com