



## Case Report

### Submandibular Swelling- Not a Cat's Play!!!

Rajeshwara. K.V<sup>\*1</sup>, Clement R.S. D'Souza<sup>2</sup>, Elroy Saldanha<sup>3</sup>

<sup>1</sup>Assistant Professor, <sup>2</sup> Professor, <sup>3</sup>Postgraduate resident, Department of Surgery, Fr. Muller Medical College Hospital, Kankanady, Mangalore – 575002, Karnataka State.

#### ABSTRACT

Toxoplasmosis is caused by *Toxoplasma Gondii*. Man gets infection by handling the cats. Toxoplasmosis can present as congenital or acquired forms. Acquired can be of disseminated or lymphadenopathic type. Submandibular lymphadenopathy as a result of Toxoplasmosis is a rare presentation. We present a case of an young girl presenting with submandibular lymphadenopathy of 2 weeks duration without any other symptoms. Excision biopsy and serological tests confirmed the diagnosis.

**KEYWORDS:** Toxoplasmosis, Submandibular Lymphadenopathy

#### INTRODUCTION

Toxoplasmosis is a parasitic infection caused by *Toxoplasma Gondii*, and it found to be having worldwide distribution. Human being is an intermediate host infected by ingestion of meat contaminated with oocysts or by contact from the faeces of members of feline family like cats. There are two types of clinical presentation like congenital or acquired. Lymphadenopathy especially in the cervical region is the usual presentation. Toxoplasmosis can be diagnosed indirectly by serological tests or directly through Polymerase Chain Reaction (PCR), hybridisation, isolation, and histology [1].

Prevention of primary infection is based upon educating women on the modes of *Toxoplasma Gondii* transmission and avoidance of risky behaviours. Fruits and vegetables should be washed before eating. Consumption of raw eggs, unpasteurized milk, or unfiltered water should be avoided as well as tasting meat while it is cooking [2].

We present a case of unexplained submandibular lymphadenopathy in an young girl who had a contact with domestic cat. Excision biopsy of the submandibular lymph node with serological tests confirmed the Toxoplasmosis.

#### CASE REPORT

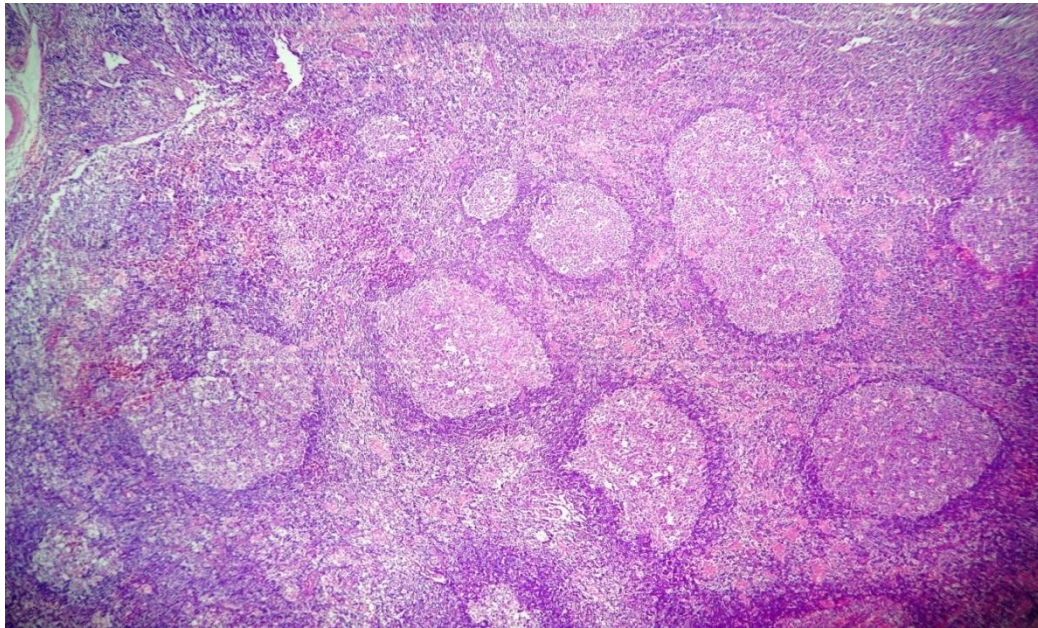
An young girl aged about 13 years presented to the surgical outpatient department with history of swelling in the right side of neck since 2 weeks. The swelling was noticed by her mother which was progressively growing in size. There was no history of cough or fever.

On examination there was a lymph node in the right submandibular region measuring 2x2 cm hard in consistency mobile and non-tender. On investigation Hb 12.2 gm.% ,TC 8,900/cmm, DC= N-39% ,L- 42%, E -17%, M-02%; ESR-06mm/Hr; S.Urea-16mg/dl; S.Creatinine-0.5 mg/dl; FNAC of Lymph Node –Features of Granulomatous Lymphadenitis.

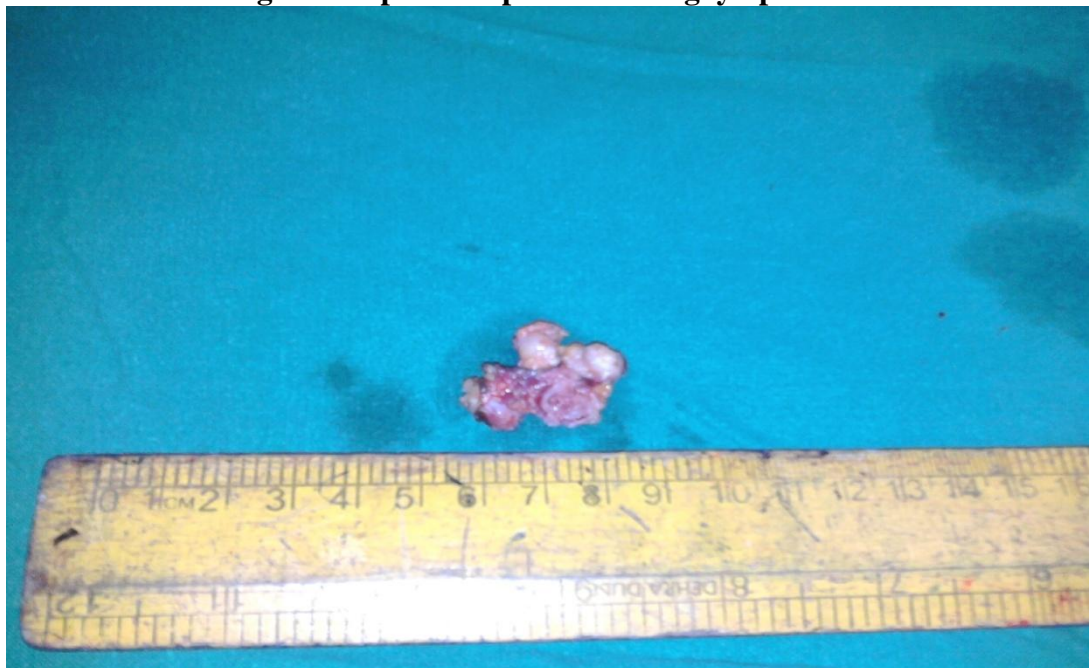Patient was admitted and Right submandibular Lymph node biopsy was done and histopathological study of the lymph node showed marked follicular hyperplasia and active germinal centres (Fig1). Focal areas shows vascular proliferation with plump endothelial cell sand histiocytes.The vessels are slightly dilated and congested with occasional micro granulomas.

Pathologist gave an impression of granulomatous lymphadenitis suggestive of Toxoplasmosis with a suggestion to confirm by serology. Serological study with IgG-131.7 and IgM-2.11 were both positive for Toxoplasmosis. Patient was advised a course of pyrimethamine and sulfadiazine and on follow up she is asymptomatic.

**Figure 1: Reactive follicular hyperplasia,cluster of epitheloid cells and patches of monocytoid B lymphocyte proliferation in lymph node**



**Figure 2: Specimen photo showing lymph node**



## DISCUSSION

Toxoplasmosis is a parasitic infection caused by the obligate parasite, *Toxoplasma Gondii*, which was first found in a North African rodent called *Gondii* [3] and later found to be widely distributed throughout the world. Human beings can be infected with *T. Gondii* by ingestion of tissue cysts in the undercooked meat of intermediate hosts, especially pork and lamb, or by the ingestion of water or food contaminated by faeces containing oocysts from the definitive host, members of the feline family.

Cats are recognized as the only definitive hosts of *T. Gondii*, but humans can be infected by the ingestion of oocysts [4]. *Toxoplasma Gondii* is an obligate intracellular parasite existing in three forms: the oocyst, shed only in cat faeces, the tachyzoite (a rapidly dividing form observed in the acute phase of infection), and the bradyzoite (a slow growing form observed within tissue cysts). During a primary infection a cat can seed millions of oocysts daily for a period of one to three weeks. These oocysts may remain infectious for over an year [5,6].

*T. Gondii* infection is generally asymptomatic or associated with lymphadenopathy and manifests as a flu-like illness in immunocompetent individuals. However, the infection causes severe and fatal complications, especially in the central nervous system, in immunocompromised individuals [7,8]. Primary infection is usually subclinical but in some patients cervical lymphadenopathy or ocular disease can be present. Infection acquired during pregnancy may cause severe damage to the foetus. In immunocompromised patients, reactivation of latent infection can cause life-threatening encephalitis.

*T. Gondii* infection can be diagnosed indirectly with serological methods and directly by Polymerase Chain Reaction (PCR), Hybridisation, Isolation, and Histology.

There are two clinical manifestations of toxoplasmosis: the congenital and the acquired forms. The congenital form is characterized by hydrocephalus, chorioretinitis, convulsions, and intracerebral calcifications in the newborn. When the infection occurs late in pregnancy, only mild

signs or symptoms may be seen at birth. In such cases, more aggressive complications such as central nervous system seizures or retinochoroiditis will be observed later in life.

The acquired form is further subdivided into the disseminated and the lymphadenopathic types, the later being the more common form of the disease in men. Acquired toxoplasmosis may be present at any age, but peak incidence is in the second and third decades. Beverley showed in his study that 30% of the toxoplasmic

Lymphadenopathy cases were in children and young adolescents [9]. It has been estimated that 15% of unexplained lymphadenopathy is due to toxoplasmosis, usually affecting the cervical lymph nodes. Lymphadenopathy is a typical and sometimes an unique sign of the acquired toxoplasmosis [10] usually of soft consistency, mobile, and sometimes painful. Cervical adenopathy usually is encountered in the posterior cervical region (82%), followed by axillary (35%), inguinal (19%), and anterior chest wall (8%). The submandibular lymph nodes are rarely involved (0.45%) [11]. In children, the cervical lymph nodes are most commonly affected.

Prior case reports have shown that the disease has a higher prevalence among men (79% versus 63.4% in women) and that age-dependent seroprevalence reaches > 92% in the age 40 to 50 groups. In seroepidemiological surveys in the USA, 11% of persons aged 6 to 49 are seropositive for *T. Gondii* [12].

### Clinical manifestations

Acute infection in adult humans goes unrecognized in as many as 90% of cases, because either it is subclinical or symptoms are nonspecific and it is falsely taken as a viral illness. The most common manifestations are nontender isolated cervical or occipital lymphadenopathy lasting for less than four to six weeks. The lymph nodes are usually discreet, non-tender, and do not suppurate. Fatigue, headache, malaise and myalgia are other associated symptoms. The infection is usually self-limited and requires no treatment.



Serologic tests represent the most commonly used method to establish the diagnosis. Documentation of recent seroconversion is the best evidence of recent infection. IgG antibodies appear within one to two weeks of infection, peak in six to eight weeks and then decline over the next two years; they remain detectable for life. IgM antibodies may appear within the first week of infection and generally decline within a few months; however, they sometimes persist for years after the initial infection. Thus, the presence of IgM antibodies should not be used to confirm a recent or acute infection.

Prevention of primary infection is based upon educating women on the modes of *Toxoplasma Gondii* transmission and avoidance of risky behaviours. Fruits and vegetables should be washed before eating. Cutting boards, knives, and the sink and counters should be washed after food preparation. Consumption of raw eggs, unpasteurized milk, or unfiltered water should be avoided as well as tasting meat while it is cooking. Smoked or cured inbrine meat is not safe. Meat should be cooked to 66°C (152° F) or higher or frozen for a day in a household freezer, both these measures are lethal to tachyzoites and bradyzoites. Mucous membrane contact when handling uncooked meat, shellfish, fruit, and vegetables should be avoided, and hands should be washed thoroughly afterwards. One should wear gloves if they are gardening or during the change of litterbox. Cats that live exclusively indoors and eat cooked food are not at risk of acquiring toxoplasmosis. Women should wash hands with soap and water after working with soil, after handling the cat or litter box, or after touching raw or undercooked meat[13].

In more severe cases, pyrimethamine and sulfadiazine are the treatment of choice. Because of its possible relationship to 15% of unexplained lymphadenopathies, toxoplasmosis should be considered in the differential diagnosis of any head and neck lymphadenopathy.

## CONCLUSION

In coastal areas because of abundant availability of marine fish cat is a common domestic animal. Children have a great affection and love towards

these feline group animals. By handling the cats there is every chance of getting infected with Toxoplasmosis. So we have to educate the children regarding the advantage of proper hand washing with soap after handling domestic animals before consuming any food. In any cervical lymphadenitis we have to keep the Toxoplasmosis as a Differential diagnosis even though it is uncommon.

## REFERENCES

1. Tuzuner N, Doqusoy G, Demirkesen C, Ozkan F, Altas K.J. *Laryngol Otol* 1996;110(4):348-52.
2. Jones JL, Muccioli C, Belfort R Jr, Holland GN, Roberts JM, Silveira C. Recently acquired *Toxoplasma gondii* infection, Brazil. *Emerg Infect Dis* 2006;12(4):582-587
3. Badri Azaz, Isaac Milhem, Oscar Hassar, Gina Kirschi. Acquired toxoplasmosis of a submandibular lymph node in a 13 year old boy. *Paediatric Dentistry* 1994;16(5):378-380
4. Kasper L, Courret N, Darche S, Luangsay S, Mennechet F, Minnis L, et al. *Toxoplasma gondii* and mucosal immunity. *Int J Parasitol* 2004;34(3):401-409
5. Montoya JG, Liesenfeld O. Toxoplasmosis. *Lancet* 2004;363(9425):1965-76.
6. Hill D, Dubey P. *Toxoplasma gondii* : transmission, diagnosis and prevention. *Clin Microbiol Infect* 2002;8(10):634-640
7. Boothroyd JC, Grigg ME. Population biology of *Toxoplasma gondii* and its relevance to human infection : do different strains cause different disease?. *Curr Opin Microbiol* 2002;5(4):438-442

8. Correa D ,Candeo-Solares I,Oriz-Alegria LB,Caballero-Ortega H,Rico Torres CP: Congenital and acquired toxoplasmosis : diversity and role of antibodies in different compartments of the host. *Parasite Immunol* 2007;29(12): 651-660
9. Beverley JK, Fleck DG, Kwantes W, Ludlan GB , Age sex distribution of various diseases with particular reference to toxoplasmic lymphadenopathy. *J . Hyg(Lond)* 1976 ;76(2):215-218
10. Sumi Y,Kaneda T,Nagasaka T: Toxoplasmosis of the preauricular and cervical lymph nodes. *Journal of Oral and Maxillofacial Surgery* 1987;45(11): 978-979
11. Gray GF Jr, Kimball AC, Kean BH. The posterior cervical lymph node in Toxoplasmosis .*Am J Pathol* 1972; 69(2) :349-58
12. Jones JL, Kruszon-Moran D,Sanders-Lewis K,Wilson M,Toxoplasma gondii infection in the United States , 1999-2004,Decline from the Prior Decade. *Am J Trop Med Hyg* 2007;77(3): 405-410
13. Giannoulis C,Zournatz B,Giomini A,Diza E,TzafettasI, Toxoplasmosis during pregnancy: a case report and review of the literature. *Hippokratia* :2008; 12(3) :139-43

---

\*Corresponding author: Dr.Rajeshwara K.V.

E-mail: [rajeshwarakv@yahoo.com](mailto:rajeshwarakv@yahoo.com)